

We can currently report on 1-month results of 10 treated eyes. Not one of the eyes lost more than 2 lines of vision, and thus the new procedure can be classified as safe. We would like to present one case as an example (Fig. 2). Both the post-operation vision of 1.0 uncorrected and the desired refraction are very satisfactory for this early phase of clinical testing. Even the topography after treatment (Fig. 3) shows a well formed optical zone with a slightly prolate form; additional wave front measurements confirm this finding.

Parameters	Pre-op	Post-op (1 month)
Sphere/cylinder/axis	-5.50 D/-0.50D/15°	+0.50 D/-0.75D/15°
UCVA	<20/200	20/20
BSCVA	20/20	20/20

Fig. 2 FLEx curtain picture (male, age 33)

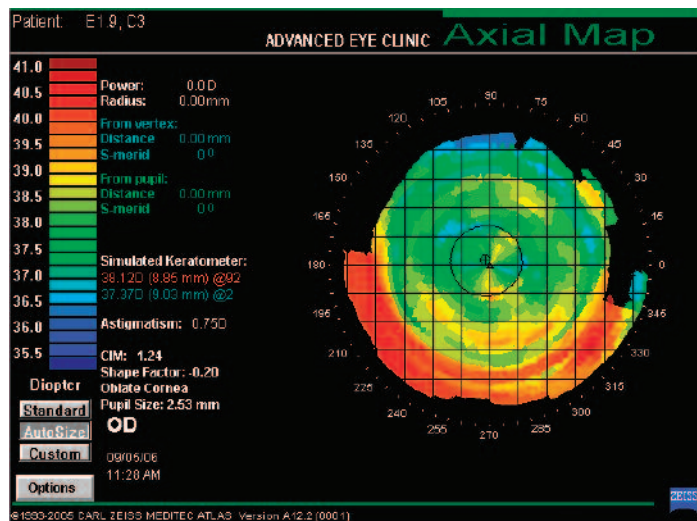


Fig. 3 Corneal topography after FLEx-treatment (4 weeks post-op)

In summary, we can currently determine for both studies that the transfer from the laboratory to clinical practice was accomplished without incident.

For the new FLEx method, the principal feasibility with the VisuMax femtosecond laser was proven. Initial results exceeded our expectations. On the basis of the very promising early results of this new procedure, we will continue this study and report subsequently on the clinical results.

LASIK flaps were cut precisely and reproducibly. The combination with the MEL 80 excimer laser results in an integrated treatment that is characterized by outstanding results and an efficient course of events.

The new VisuMax femtosecond laser has already given impressive proof of its potential for a broad refractive-surgical spectrum of applications in clinical use.

Glossary

Flap - Lamella of the foremost corneal layer

fs - a femtosecond equals 10^{-15} seconds